

Surgical Technique

Protection of the Femoral Trunnion During Acetabular Revision Hip Surgery—A Novel Technique

Abhijit C. Kawalkar, MBBS, MS (Orth), DNB (Orth), MNAMS^{a,*},
 Nick Vertzyas, MBBS, FRACS(Orth), FA OrthA^b,
 Michael J. Neil, MBBS, FRCS Ed(ORTH), FRACS, FA OrthA^c

^a Orthopaedic and Joint Replacement Surgeon, Orange City Hospital and Research Institute, Nagpur, India

^b Orthopaedic Surgeon, & Chairman, Department of Orthopaedics, St Vincent's Clinic and Private Hospital, Sydney, New South Wales, Australia

^c Conjoint Associate Professor UNSW, Adjunct Associate Professor U Notre Dame, Orthopaedic Surgeon and Director, St Vincent's Bone and Joint, St Vincent's Clinic and Private Hospital, Sydney, New South Wales, Australia

ARTICLE INFO

Article history:

Received 27 May 2020

Received in revised form

22 September 2020

Accepted 27 September 2020

Available online xxx

Keywords:

Trunnion

Liner exchange

Cup-only revision

Silicon sleeve

ABSTRACT

Revision of a failed acetabular component in the presence of an intact femoral prosthesis comprises approximately 20% of revision total hip replacements performed by the senior author. During this procedure, the femoral trunnion is at risk of damage because of scratching from retractors, reamers, or other instruments. Scratching can result in mechanically assisted crevice corrosion or adverse local-tissue reaction or trunnionosis leading to implant failure. We have used a variety of techniques for protection of the femoral taper over the last 30 years. We describe our current method of taper protection, using a cut segment of #5 silicon laryngeal airway, which is a simple and effective method.

© 2020 The Authors. Published by Elsevier Inc. on behalf of The American Association of Hip and Knee Surgeons. This is an open access article under the CC BY-NC-ND license (<http://creativecommons.org/licenses/by-nc-nd/4.0/>).

Introduction

Mechanically assisted crevice corrosion or adverse local-tissue reaction [1], previously known as trunnionosis, is defined as wear and corrosion of the femoral head neck taper interface [2] and has been acknowledged as a growing cause of total hip arthroplasty failure [3]. It is believed to be a synergistic combination of factors and involves both fretting corrosion and crevice corrosion [4]. The trunnion should be rinsed, cleaned, and dried carefully, while avoiding any contamination of the bore before assembly. Biological debris, and even residual water, might critically reduce the fixation of the taper connection between the head and the neck [5].

Revision hip arthroplasty consisting of both components accounts for approximately 41% of procedures, whereas isolated cup-only revisions including liner exchange account for about 26% [6]. One of the most difficult problems with isolated acetabular revision

surgery or liner exchange is getting adequate exposure without damaging the femoral trunnion. The anterior and posterior acetabular wall retractors can scratch the trunnion leading to mechanically assisted crevice corrosion, which can be of various degrees as described by Goldberg et al [7] [Table 1]. Thus, it is important to avoid superficial scratching or damage to the femoral trunnion and to prevent its contamination from debris and even blood, which could lead to failure of the implant [2,8,9].

Over a 30-year period, we have used various methods for intraoperative trunnion protection. The most recent technique uses a cut segment of #5 silicon laryngeal airway that is applied directly over the femoral trunnion. We have found this to be a safe and reliable as well as a simple intraoperative technique. We describe this in detail.

Operative technique

We use a mini-posterior approach, but the technique is applicable to all surgical approaches. After dislocation of the hip, the femoral head is removed and the taper inspected and cleaned. A 1-inch segment of #5 laryngeal airway is applied directly over the Morse taper (Fig. 1). This tubing seems to fit snugly for tapers

* Corresponding author. Orange City Hospital and Research Institute, 1003, Neelkanth Apartment, Pande Layout, Khamla, Nagpur, 440025 Maharashtra, India. +Tel.: 919552149603.

E-mail address: dr.abhijitkawalkar@gmail.com

Table 1
Criteria for corrosion and fretting scores by Goldberg et al. [7].

Severity of corrosion and fretting	Score	Criteria
None	1	No visible corrosion observed No visible signs of fretting observed
Mild	2	<30% of taper surface discolored or dull Single band or bands of fretting scars involving 3 or fewer machine lines on the taper surface
Moderate	3	>30% of the taper surface discolored or dull, or <10% of the taper surface containing black debris, pits, or etch marks Several bands of fretting scars or a single band involving more than 3 machine lines
Severe	4	>10% of the taper surface containing black debris, pits, or etch marks Several bands of fretting scars involving several adjacent machine lines, or flattened areas with nearby fretting scars

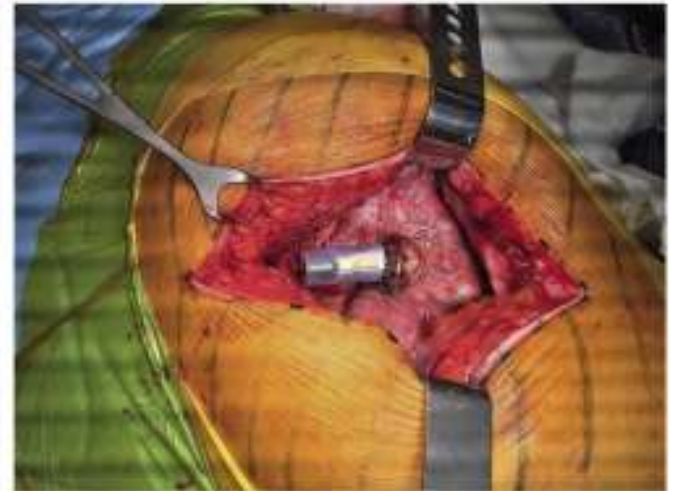


Figure 2. Intraoperative photograph of femoral taper protection with the laryngeal airway sleeve.

ranging from 11/13, 12/14, to even rarely 14/16. It is less tight on the smaller tapers such as V40.

For the posterior approach, the femoral prosthesis is then retracted anteriorly into a subgluteal pocket. A curved Hohmann retractor is placed anterior to the acetabulum with the femoral component levered behind it. The silicon sleeve protects the trunnion from metal-on-metal contact and scratching in spite of leverage directly by the instruments (Fig. 2).

Discussion

Protection of the femoral trunnion is the important aspect of isolated acetabular revision. By avoiding damage to the femoral trunnion, we avoid the risk of mismatch of the mating surfaces, corrosion, and particle generation [10,11].

There have been various methods described to provide femoral taper protection including cotton swab covers, multiple rubber

finger stalls, and simple syringes. We have had experience with all these methods and have found the laryngeal airway technique to be the easiest and most effective [12,13].

A #5 laryngeal airway is available in most modern operating theaters, is easily cut using a scalpel blade, remains stable on most femoral tapers, and is resilient to avoid tearing or breakage. We have used this technique in more than 100 cases without failure.

Summary

We consider that the aforementioned procedure is an inexpensive and simple solution for the complicated problem and strongly recommend to be used during all liner exchange and acetabular cup-only revision total hip replacement surgeries.



Figure 1. Silicon laryngeal airway #5 and its cut segment applied to the femoral taper.

Conflict of interests

N. Vertzyas receives royalties from Corin (Paragon collar royalties) and is a paid consultant for Corin (robotic knee platform); M.J. Neil receives royalties from Global Paragon hip prosthesis and Global Orthopaedic Technology, Australia, and is a paid consultant for Global Orthopaedic Technology, Australia; and A.C. Kawalkar declares no potential conflicts of interest.

References

- [1] McGroary BJ, Joshua JJ, Young MK, Fillingham Y. Standardizing terms for tribocorrosion-associated adverse local tissue reactions in total hip arthroplasty. *Arthroplasty Today* 2020;5:196.
- [2] Rehmer A, Bishop NE, Mocklock MM. Influence of assembly procedure and material combination on the strength of the taper connection at the head-neck junction of modular hip endoprostheses. *Clin Biomech (Bristol, Avon)* 2012;27:77.
- [3] Paschides PS, Dodd M, Sarraf KM, Willis-Owen CA. Trunnionosis: a pain in the neck. *World J Orthop* 2013;4(4):161.
- [4] Jacobs JJ, Gilbert JL, Urban RM. Corrosion of metal orthopaedic implants. *J Bone Joint Surg Am* 1998;80:268.
- [5] Rieker CB, Wahl P. What the surgeon can do to reduce the risk of trunnionosis in hip arthroplasty: recommendations from the literature. *Materials (Basel)* 2020;13:1950.
- [6] Katz JN, J Wright E. A wright and E losina failures of total hip replacement: a population-based perspective. *Orthop J Harvard Med Sch* 2007;9:101106.
- [7] Goldberg JR, Gilbert JL, Jacobs JJ, Bauer TW, Paprosky W, Leurgans S. A multicenter retrieval study of the taper interfaces of modular hip prostheses. *Clin Orthop Relat Res* 2002;401:149.
- [8] Cooper HJ, Della Valle CJ, Berger RA, et al. Corrosion at the head-neck taper as a cause for adverse local tissue reactions after total hip arthroplasty. *J Bone Joint Surg Am* 2012;94(18):1655.
- [9] Banerjee S, Cherian JJ, Bono JV, et al. Gross Trunnion failure after primary total hip arthroplasty. *J Arthroplasty* 2015;30(4):641.
- [10] Cook SD, Barwick RL, Raffles GC, et al. Wear and corrosion of modular interfaces in total hip replacement. *Clin Orthop Relat Res* 1994;298:80.
- [11] Lieberman JR, Rimmac CM, Garvin RL, Klein RW, Salvati EA. Analysis of the head-neck taper interface in retrieved hip prostheses. *Clin Orthop Relat Res* 1994;300:162.
- [12] Piniakka T, Halonen P, Oksa J, et al. Protection of femoral neck taper in revision of acetabular component. *J Arthroplasty* 2002;17:497.
- [13] Neil MJ, Solomon MI. A technique of revision of failed acetabular components leaving the femoral component in situ. *J Arthroplasty* 1996;11(4):482.