

## Management of Distal Femur Periprosthetic Fracture in Elderly Female with Distal Femur Replacement: A Case Report

Michael J Neil<sup>1</sup>, Abhijit C Kawalkar<sup>2\*</sup>, Amir Kalanie<sup>3</sup>

<sup>1</sup>Conjoint Associate Professor UNSW, Adjunct Associate Professor U Notre Dame, Orthopaedic Surgeon and Director, St. Vincent's Bone and Joint, St. Vincent's Clinic, Sydney, Australia

<sup>2</sup>Arthroplasty Fellow, St. Vincent's Bone and Joint, St. Vincent's Clinic, Sydney, Australia

<sup>3</sup>Conjoint lecturer UNSW, Adjunct lecturer U Notre Dame, Orthopaedic Surgeon, St. Vincent's Bone and Joint, St. Vincent's Clinic, Sydney, Australia

\*Corresponding author: Abhijit C Kawalkar, Arthroplasty Fellow, St. Vincent's Bone and Joint, St. Vincent's Clinic, Sydney, Australia, Tel: 0421450865; E-mail: [dr.abhijitkawalkar@gmail.com](mailto:dr.abhijitkawalkar@gmail.com)

Received date: 03 Oct 2017; Accepted date: 13 Oct 2017; Published date: 20 Oct 2017.

Citation: Neil MJ, Kawalkar AC, Kalanie A (2017) Management of Distal Femur Periprosthetic Fracture in Elderly Female with Distal Femur Replacement: A Case Report. J Clin Case Stu 2(5): doi <http://dx.doi.org/10.16966/2471-4925.153>

Copyright: © 2017 Neil MJ, et al. This is an open-access article distributed under the terms of the Creative Commons Attribution License, which permits unrestricted use, distribution, and reproduction in any medium, provided the original author and source are credited.

### Abstract

Periprosthetic distal femur fractures after total knee arthroplasty are a relatively rare complication but are complex injuries with very high complication rates. Closed or open reduction with internal fixation with either locked plate or intramedullary nail is the most commonly used for treating these fractures. Success of these methods depends on the fracture pattern, the stability of implants, and the patient's bone quality which is often poor in elderly, thus resulting in high complication rates. Also the patients need to be non-weight bearing for 6 weeks which often makes elderly patients non ambulant, predisposing them to life threatening complications like deep vein thrombosis, pulmonary embolism and respiratory infections. Distal femoral replacement is another option for management of these complex fractures, which allows immediate mobilization of the patients and the results does not depend on bony union at the fracture site which is often difficult to achieve in elderly patients. Although this is a technically difficult procedure but when performed properly can be the best treatment options in elderly patients. We present here a 90 years old active female with distal femur periprosthetic fracture with complex revision total knee prosthesis in situ sustained due to trivial fall, which was managed by distal femoral replacement using limb construction system hinge prosthesis with excellent functional outcome.

**Keywords:** Periprosthetic Fracture; Distal Femur Replacement; Limb Reconstruction System; Elderly Patient

### Introduction

The number of knee replacement procedures performed annually is increasing dramatically. It is, therefore, expected that the incidence of periprosthetic fractures around the knee associated with primary and revision total knee arthroplasty (TKA) will also rise [1]. The rate of periprosthetic fractures after TKA is 0.1%-2.5%. The most common periprosthetic fracture is that of the distal femur with an incidence of 0.3%-2.5% after primary TKA and 1.6- 38% after revision TKA [2,3]. In particular, patients aged  $\geq 70$  years are 1.6 times more likely to have a fracture than younger patients and women are overall 2.3 times more likely to suffer a fracture than men [4].

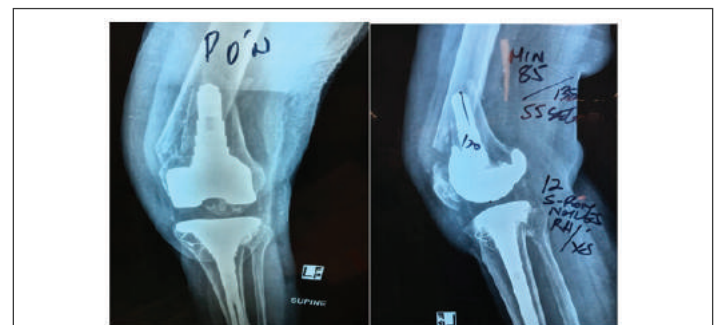Osteopenia appears to be an important predisposing factor contributing to periprosthetic fractures. Other risk factors include old age, chronic corticosteroid use, inflammatory arthritis, local osteolysis and significant deformity or previous surgery [1]. Majority of these fractures occur following minor trauma after a simple fall. Other causes include road-traffic accidents, seizures and forced manipulation of a stiff knee.

These fractures are of great concern due to its intricate connections with the patient's quality of life. Management of patients with distal femoral periprosthetic fractures can often be difficult due to the complexity of these injuries and the requirement for technical expertise in both trauma and knee revision surgery; also there management is a time and resource consuming with very high complication rates. The most important challenges faced include poor bone stock and a diminished healing capacity with poor biological and physiological reserve in the elderly [4,5]. Treatment goals are to achieve painless and stable knees with excellent alignment and range of motion. Prolonged immobilization

in these patients may results in decreased range of motion, reduced walking capacity, and higher rates of complications [3]. In this case report we present a complicated supracondylar periprosthetic fracture with the revision total knee arthroplasty implant in situ managed with distal femoral replacement in nonagenarian female.

### Case report

90 years active female presented to us with trivial fall from standing height with severe pain and swelling over left knee. She is in excellent health and very active with previous history of deep vein thrombosis (DVT). Radiograph showed Type II Lewis and Rorabeck supracondylar distal femur fracture (Figure 1). Patient had well fixed S-ROM stemmed knee implant with metaphyseal sleeves in situ which was implanted 27 years back after a complex revision total knee arthroplasty. But given the nature of the fracture and its extension around the femoral component,



**Figure 1:** Peri prosthetic distal femur fracture (Lewis and Rorabeck type-II)

there was a possibility that the component might be loose. So after weighing all the options and meticulous pre-operative planning the patient was posted for distal femoral replacement using limb preservation system (DePuy LPS™ Limb Preservation System) (Figure 2). Patient was operated under spinal with general anesthesia and femoral nerve block was given for post operative pain relief. Previous scar was incorporated in the incision and was extended proximally. Arthrotomy was done using extended parapatellar approach and medial and lateral release was done to facilitate exposure. Tibial component was well fixed and it was impossible to remove it without destroying the proximal tibia with significant bone defect. So it was decided to retain the tibial base plate and the poly insert was removed. Most important step was to dissect the distal femur without injuring the neurovascular bundle, which was done by meticulous subperiosteal dissection (Figure 3). Length of dissected femur was measured (130 mm) and same was built up using the distal femur limb preservation system to maintain the joint line. A super cable was placed on the distal end of femur shaft to prevent the fracture at this end. The distal shaft of femur was prepared using sequential reamers and the distal femur component was fixed using cement less porous coated sleeve with extension rod. The trail was done using sequential trail liners to accommodate the hinge mechanism of distal femur component. 15 mm rotating platform poly insert was found to maintain the soft tissue balance and was replaced with real poly liner (Figure 4). Heamostasis was achieved and the wound was closed under negative suction drain and local anesthetic pain catheter (ON-Q® PainBuster® - B. Braun). A compressive dressing was applied and knee placed in extension knee splint.

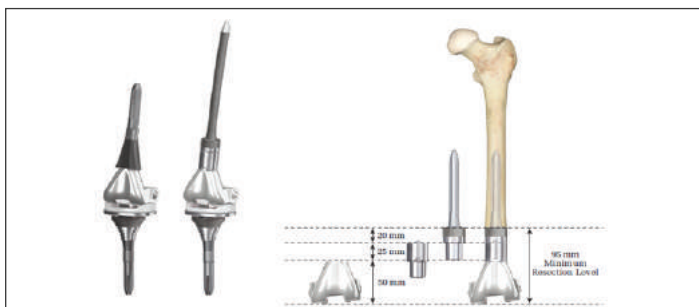


Figure 2: Distal femur limb reconstruction system

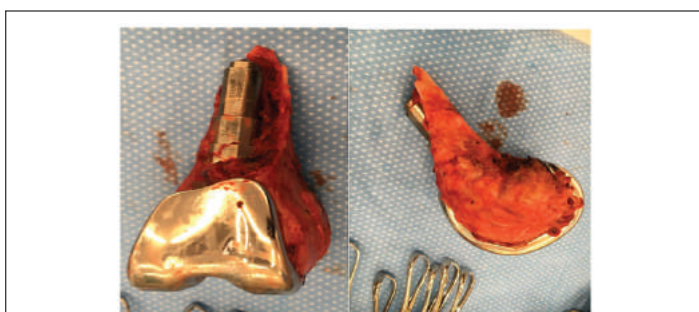

Figure 3: Sub periosteally resected distal femur

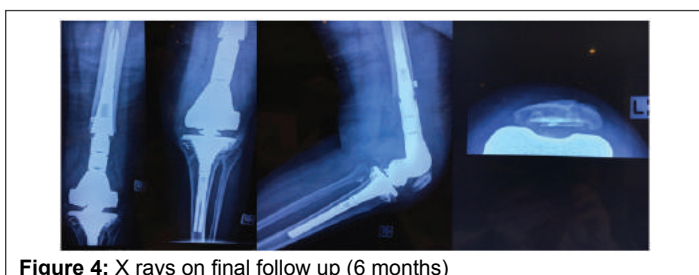

Figure 4: X rays on final follow up (6 months)

The suction drain and pain buster were removed after 48 hours without removing the dressing over the surgical wound. Patient was placed under supervised physiotherapy regimen for knee bending and muscle strengthening exercises. Partial weight bearing with extension knee splint and crutches was allowed from the first post operative day. Full weight bearing without knee splint was started after 2 weeks. At the last follow up (6 months) patient was walking unassisted with full weight bearing and the knee range of motion was 0 to 110 degrees. Wound has healed well without complications. But the patients have post traumatic arthritis of ipsilateral hip for which the surgery will be planned subsequently.

## Discussion

Most commonly used treatment options for periprosthetic distal femur fractures after total knee arthroplasty are open or closed reduction and internal fixation with either locked plates or intramedullary nail. Both these treatment options have high rates of complications like malunion, non-union and fixation failures [6,7]. These complication rates are expected as the problem in itself is very complex. But the major issue with these treatment options is that the patient needs to be non-weight bearing for around 6 weeks and non-weight bearing mobilization is not possible in most of the patients especially elderly due to various co-existent problems such as arthritis in hand and shoulder joints and balance issues. Thus making these patients bed ridden which not only leads to decreased range of motion, reduced walking capacity, and higher rates of malunion but also puts these patients at risk of deep vein thrombosis, pulmonary embolism and chest infections which can be life threatening [8].

Primary goals of treatment for these fractures especially in elderly should be to achieve well aligned painless stable knee joint allowing early ambulation thus restoring TKA function [9]. Thus distal femoral replacement in our view is ideal treatment option in elderly patients with distal femur periprosthetic fractures with associated medical comorbidities, who do not tolerate bed rest or weight-bearing restrictions as it allows immediate ambulation. Moreover, these patients are prone to treatment failure secondary to poor-healing capacity. But this option should not be used for younger and high demand patients as there are high chances of failure due to loosening of prosthesis.

The most common complication of distal femoral replacement is infection (15%), followed by aseptic loosening (5%), and periprosthetic fractures (5%). The mortality rate averaged 22%. Thus when compared to other treatment options and period of immobilization required after these methods, distal femoral replacement as a limb salvage option in elderly patients with limited life expectancy is highly effective [10]. Though the cost of prosthesis is higher than the plates or nails but decreased hospital stay shortened post operative care compensates for this cost.

## Conclusion

Distal femur endoprosthetic reconstruction is a safe and reliable technique of for management of periprosthetic distal femur fracture in elderly, low demand patients with revision knee prosthesis, providing good functional outcome.

## Conflict of Interest

None

## References

1. Whitehouse MR, Mehendale S (2014) Periprosthetic fractures around the knee: current concepts and advances in management. *Curr Rev Musculoskelet Med* 7: 136-144.
2. Merkel KD, Johnson EW Jr (1986) Supracondylar fracture of the femur after total knee arthroplasty. *J Bone Joint Surg Am* 68: 29-43.

3. Agarwal S, Sharma RK, Jain JK (2014) Periprosthetic fractures after total knee arthroplasty. *J Orthop Surg* 22: 24-29.
4. Sarmah SS, Patel S, Reading G, El-Husseiny M, Douglas S, et al. (2012) Periprosthetic fractures around total knee arthroplasty. *Ann R Coll Surg Engl* 94: 302-307.
5. Herrera DA, Kregor PJ, Cole PA, Levy BA, Jönsson A, et al. (2008) Treatment of acute distal femur fractures above a total knee arthroplasty: systematic review of 415 cases (1981-2006). *Acta Orthop* 79: 22-27.
6. Ebraheim NA, Liu J, Hashmi SZ, Sochacki KR, Moral MZ, et al. (2012) High complication rate in locking plate fixation of lower periprosthetic distal femur fractures in patients with total knee arthroplasties. *J Arthroplasty* 27: 809-813.
7. Parrón R, Tomé F, Pajares S, Herrera JA, Madruga JM, et al. (2007) Treatment of periprosthetic knee fractures in the distal femur by means of retrograde intramedullary nailing. *Rev Ortop Traumatol (Madr)* 51: 314-318.
8. Berend KR, Lombardi AV Jr (2009) Distal femoral replacement in nontumor cases with severe bone loss and instability. *Clin Orthop Relat Res* 467: 485-492.
9. Abolghasemian M, Kim C, Soever L, Backstein D (2015) Megaprotheses for well-fixed TKA femoral fractures. *Seminars in arthroplasty* 26: 95-99.
10. Korim MT, Esler CN, Reddy VR, Ashford RU (2013) A systematic review of endoprosthetic replacement for non-tumour indications around the knee joint. *Knee* 20: 367-375.